ORANGE COUNTY SHERIFF-CORONER
1071 W. Santa Ana Blvd.
Santa Ana, CA 92703

Michael S. Carona, Sheriff-Coroner

Autopsy Record

DECEDENT:	BROWN, Henry Lee	CASE NUMBER: 04-04421-LO

RESIDENCE:

CITY: STATE/ZIP:

AGE: 52 Years DOB: 2/21/1952 SEX: Male RACE: Black

PLACE OF DEATH: Riverbed

ADDRESS: 27912 Baker Canyon Road

CITY: Silverado STATE: CA ZIP CODE 92676

DATE/TIME OF DEATH: 06/12/2004 16:00 Est.

CAUSE OF DEATH: Multiple gunshot wounds

OTHER CONDITIONS: None

AUTOPSY DATE/TIME: 06/13/2004 6:07

PLACE OF AUTOPSY: Sheriff-Coroner Forensic Science Center
1071 W. Santa Ana Blvd.
Santa Ana, CA 92703

AUTOPSY ATTENDANTS: Joe Jaing, OCSD; Erika George, OCSD; A. Spencer, OCSD; Jae P. Simon, OCCO; E. Gomez, OCDA

DATE D. C. ISSUED: 6/13/2004

DATE AMENDED: 2/2/2005

MANNER: Homicide

Joseph I. Cohen, M.D.
Forensic Pathologist

ORANGE COUNTY SHERIFF-CORONER
1071 W. Santa Ana Blvd.
Santa Ana, CA 92703

Michael S. Carona, Sheriff-Coroner

Autopsy Record

DECEDENT:	BROWN, Henry Lee	CASE NUMBER: 04-04421-LO

RESIDENCE:

CITY: STATE/ZIP:

AGE: 52 Years DOB: 2/21/1952 SEX: Male RACE: Black

PLACE OF DEATH: Riverbed

ADDRESS: 27912 Baker Canyon Road

CITY: Silverado STATE: CA ZIP CODE 92676

DATE/TIME OF DEATH: 06/12/2004 16:00 Est.

CAUSE OF DEATH: Pending Investigation

OTHER CONDITIONS:

AUTOPSY DATE/TIME: 06/13/2004 6:07

PLACE OF AUTOPSY: Sheriff-Coroner Forensic Science Center
1071 W. Santa Ana Blvd.
Santa Ana, CA 92703

AUTOPSY ATTENDANTS: Joe Jaing, OCSD; Erika George, OCSD; A. Spencer, OCSD; Jae P. Simon, OCCO; E. Gomez, OCDA

DATE D. C. ISSUED: 6/13/2004 MANNER: Pending

DATE AMENDED:

Joseph I. Cohen, M.D.
Forensic Pathologist

NAME OF DECEDENT: BROWN, HENRY LEE

DIAGNOSES:

I. Penetrating gunshot wound to posterior right shoulder, with:
   A. Subcutaneous and intramuscular hemorrhage.
   B. Perforations of right clavicle and thyroid cartilage.
   C. Subdural hemorrhage, cervical vertebrae, slight.
   D. Bullet recovered from left submandibular tissue.

II. Perforating gunshot wound to right thigh, with:
   A. Subcutaneous and intramuscular hemorrhage.

III. Penetrating gunshot wound to right ankle, with:
   A. Subcutaneous and intramuscular hemorrhage.
   B. Bullet recovered from plantar foot.

IV. Subdural hemorrhage, base of skull, minimal.

V. Horizontal scars, anterior wrist, multiple, bilateral.

CAUSE OF DEATH: **PENDING SHERIFF-CORONER REVIEW**

"I hereby certify that I, Joseph I. Cohen, M.D., Chief Forensic Pathologist of Riverside County, California, have performed an autopsy on the body of Henry Lee Brown on the 13th day of June, 2004, commencing at 9:35 a.m. at the office of the Orange County Sheriff-Coroner. The autopsy was completed at 11:50 a.m."

EXTERNAL EXAMINATION: The body is that of a thin, well-developed, 70 inch, 144 lb., brown-skinned man, whose appearance is consistent with the stated age of 52 years. The scalp hair is dark and markedly short, measuring approximately 1/4 inch or less. There is slight mustache and beard stubble. The irides are brown and the conjunctivae are free of petechiae, jaundice or hemorrhage. The oral cavity is free of injury. The genitalia are of a normal, non-circumcised, adult man.

There are several (approximately 4 or 5 on each wrist) horizontally situated scars on the anterior aspects of both wrists. The thin scars measure approximately 1/2 to 2 inches each. The fingernails are markedly short and dirty. There are no injuries to the hands. There is no injury to the left foot. Injuries to the right foot are described below.

7/21/2004:mm
04-04421:a

Joseph I. Cohen, M.D., Forensic Pathologist

There is a 1 inch scar on the medial aspect of the right knee, and there are 1/2 inch and 3/4 inch circular scars on the mid right shin. A 3/8 inch circular scar is on the lateral aspect of the proximal left leg. There is a subcutaneous papule on the mid left back.

The decedent is received in a white body bag containing two toe tags on the right great toe and one on the left great toe.

There is no edema of the extremities. Injuries to the body are described below.

POSTMORTEM CHANGES: Rigor mortis is slight and easily broken in the upper extremities and moderate and symmetrical in the lower extremities. Livor mortis is slight and blanches on the posterior portions of the body, and the body is cool due to refrigeration.

CLOTHING: There is no clothing on the body at the time of the examination.

THERAPEUTIC PROCEDURES: There are four electrocardiograph pads on the posterior torso, two on the lower back, and one on the superior aspect of each buttock.

There are small accumulations of fly eggs on the medial canthus of the left eye, and on the scrotum.

INJURIES, EXTERNAL AND INTERNAL: There are three gunshot wounds to the body including a penetrating gunshot wound to the posterior aspect of the right shoulder, a perforating gunshot wound to the anterior aspect of the right thigh and a penetrating gunshot wound to the lateral aspect of the right ankle. The gunshot wounds are lettered for descriptive purposes only; no sequence is implied. Directions of travel of the bullets are stated with the body in the normal anatomic position as a reference.

PENETRATING GUNSHOT WOUND TO RIGHT SHOULDER: There is a penetrating gunshot wound to the posterior aspect of the right shoulder, 16 inches below the top of the head and 6-1/2 inches to the right of midline. The 3/16 inch oval perforation has a variable, 1/16 to 1/8 inch irregular margin of abrasion. There is no fouling or stippling noted on the skin adjacent to the perforation.

After perforating the skin of the posterior right shoulder, the bullet passed through subcutaneous and intramuscular tissue prior to grazing the posterior aspect of the medial right clavicle and perforating the superior cornu of the thyroid cartilage. There are no apparent perforations of the

great vessels of the neck, however, there is marked hemorrhage along the wound track. The bullet lodged in the subcutaneous tissue of the left submandibular area where there is marked, focal hemorrhage. The bullet did not enter the chest cavity. There is no aspiration of blood within the airways.

The direction of travel is back-to-front, right-to-left, and upward. The bullet is retained.

PERFORATING GUNSHOT WOUND TO RIGHT THIGH: There is a perforating gunshot wound to the anterior aspect of the right thigh, 42 inches below the top of the head. The entrance defect is a 1/8 inch circular perforation with a 1/16 to 1/8 inch margin of abrasion. The defect is on the medial aspect of the thigh. There is no fouling or stippling noted on the adjacent skin surrounding the perforation.

After perforating the skin, the bullet passed through the thigh causing subcutaneous and intramuscular hemorrhage.

The exit wound is on the upper portion of the posterior right thigh and consists of a 3/8 inch irregular defect 39 inches below the top of the head. Radiography reveals lead snow storm appearance due to multiple minute bullet fragments.

The direction of travel is front-to-back, slightly upward, and slightly left-to-right. No bullet or fragments are recovered.

PENETRATING GUNSHOT WOUND TO RIGHT ANKLE: There is a penetrating gunshot wound to the lateral aspect of the right ankle which consists of a 1/8 inch circular perforation with a barely perceptible margin of abrasion. A bullet is noted on the radiograph at the base of the foot. The entrance defect on the lateral aspect of the right ankle is 3-3/4 inches above the base of the heel. No fouling or stippling is noted on the adjacent skin surrounding the perforation.

The projectile passed downward and lodged in the plantar region of the anterior aspect of the foot. There is focal subcutaneous hemorrhage associated with the site of lodgment.

The direction of travel is downward and slightly right-to-left. The bullet is recovered and retained.

7/21/2004:mm
04-04421:a

Joseph I. Cohen, M.D., Forensic Pathologist

INTERNAL EXAMINATION:

BODY CAVITIES: The organs are in the usual situs. There are no pericardial, pleural or peritoneal fluid accumulations. The surfaces are smooth and glistening.

HEAD: The scalp is atraumatic. There are no skull fractures, and there is no epidural or subarachnoid hemorrhage. There is minimal, thin subdural hemorrhage at the base of the brain at the right orbital plate and right middle fossa. There is no space occupying hematoma. The 1,440 gm brain is symmetrical and has normal gyri and sulci. The leptomeninges are smooth, delicate and transparent, and the leptomeningeal vessels are normal. The arteries at the base of the brain are free of atherosclerosis. The cranial nerves have normal distributions. The surfaces of the brainstem and cerebellum are unremarkable.

The cortical gray matter, subcortical and deep white matter, deep gray nuclei and ventricles are normal. The cerebrospinal fluid is clear. Horizontal sections of the brainstem and cerebellum are unremarkable.

NECK: Injuries to the neck were noted above. The cervical vertebrae are unremarkable. The hyoid is normal. The tracheal and laryngeal cartilages and paratracheal soft tissues are unremarkable, except where noted previously. The upper airway is not obstructed. The tongue is unremarkable. There is a very slight, thin, patchy subdural hemorrhage overlying the mid cervical spinal cord. There is no perceptible softening of the spinal cord.

CARDIOVASCULAR SYSTEM: The aorta and branches have minimal atherosclerosis with fatty streaks. The venae cavae and pulmonary arteries have no thrombus or embolus.

The 350 gm heart has a normal distribution of patent, right dominant coronary arteries. The epicardial vessels are unremarkable. The myocardium is uniformly red-brown without hemorrhage, softening or pallor. The left ventricular wall thickness is 1.2 cm. There is no apparent hypertrophy of the myocardium. The endocardial surfaces, heart valves, chordae tendineae and papillary muscles are normal.

RESPIRATORY SYSTEM: The right lung weighs 580 gm, and the left lung, 500 gm. The upper lobe of the right lung is dark red and markedly wet while the remaining lobes of the right lung and all of the lobes of the left lung are soft and spongy, and moist. There is no consolidation. The lungs are well inflated. The visceral pleural surfaces are smooth and glistening. The bronchi are not obstructed. The vessels have no thrombus or embolus.

Joseph I. Cohen, M.D., Forensic Pathologist

LIVER, GALLBLADDER, PANCREAS: The 1,570 gm liver has a smooth, intact capsule. The parenchyma is diffusely red-brown and wet; the bile ducts are unremarkable. The gallbladder contains approximately 25 cc of dark green, viscid bile without stones. The pancreas is uniformly tan-gray and has a normal lobular appearance.

HEMIC AND LYMPHATIC SYSTEMS: The 80 gm spleen is small with a smooth, intact capsule. The parenchyma is red and moist with slightly distinct follicles. There are several moderately enlarged lymph nodes noted within the femoral regions. There are no other lymph node enlargements. The thymus is atrophic. The bone marrow of the ribs and clavicles is unremarkable.

GENITOURINARY SYSTEM: The kidneys weigh 120 gm each. The cortices are smooth and the parenchyma is red and moist with slightly distinct corticomedullary junctions. The calyces and pelves are empty, opening into ureters which maintain uniform caliber and open into an unremarkable urinary bladder containing 30 cc of clear, yellow urine. The prostate and testes are unremarkable.

ENDOCRINE SYSTEM: The pituitary is unremarkable. The thyroid and adrenals are normal. The thyroid is not appreciably pale.

DIGESTIVE SYSTEM: The esophagus is unremarkable. The stomach contains approximately 300 cc of partially digested, greenish-beige, nondescript food. The small and large intestines, and appendix are unremarkable.

MUSCULOSKELETAL SYSTEM: The musculature is well developed though slightly to moderately atrophic. There are no fractures of the axial skeleton.

The following specimens are retained: heart blood, brain tissue, liver tissue, gastric contents, urine and vitreous. The bullets (2) are retained.

Full body radiographs, and photographs are performed.

Tissues are submitted for microscopic evaluation.

7/21/2004:mm
04-04421:a

Joseph I. Cohen, M.D., Forensic Pathologist

04-04421-LO
BROWN, Henry Lee
52 Years
DOD: 06/12/2004 1600
Male

AUTOPSY RECORD

RCVD Whole Body Bag
HAIR DARK (very short ~1/4") Black
BODY HAIR SKIN (Brown) BROWN, THIN (mod)
FEET ΦΦΦ ΦΦΦ 70" 144#
(M) stubble
(B) stubble

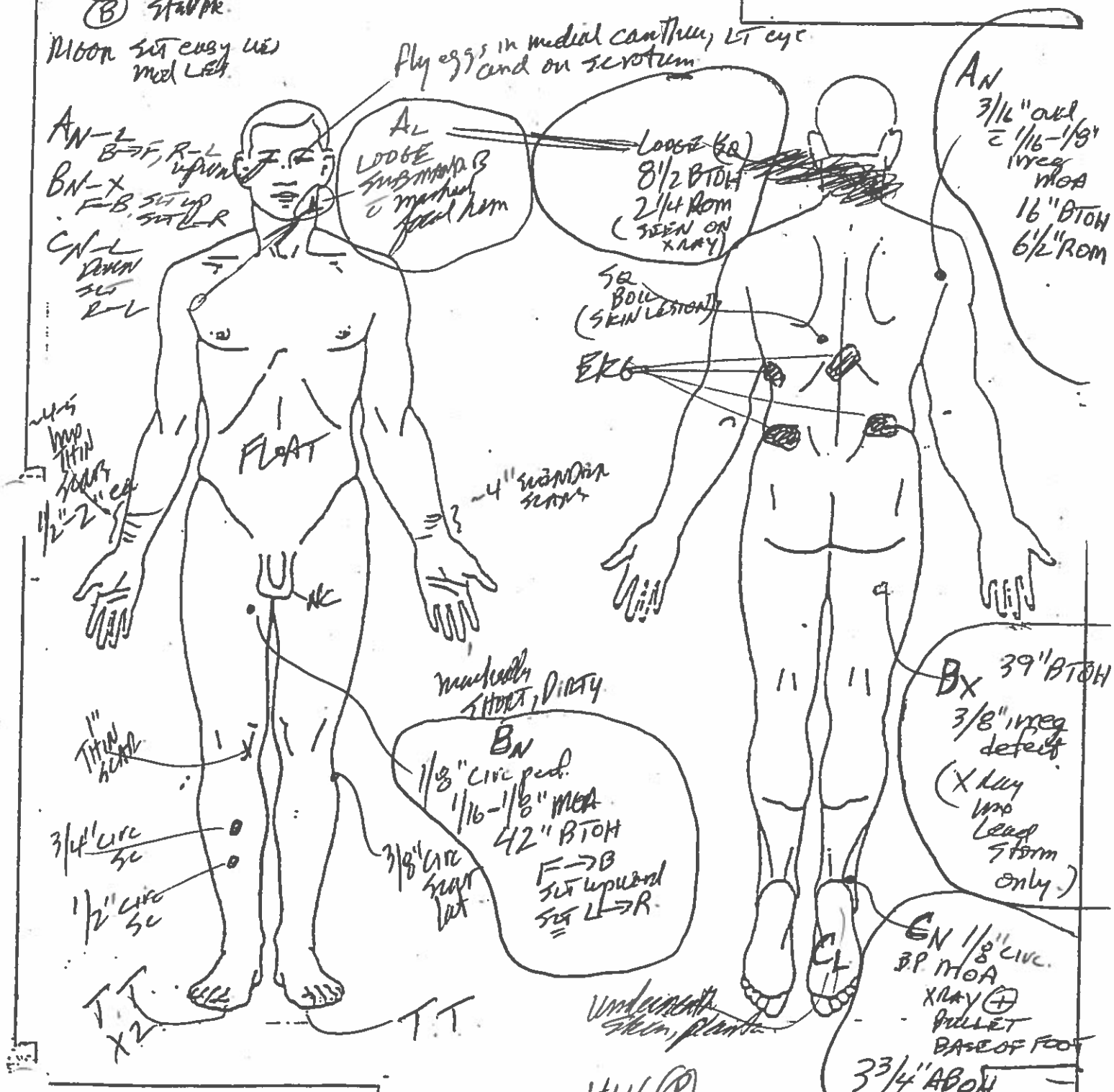

HIV ⊕
⊕ stretch marks abd / Buttocks
⊕ palp. L iss femoral

COHEN M.D.

Orange County Sheriff-Coroner
Forensic Science Services / Toxicology Laboratory
Report of Toxicological Examination

FR NUMBER: 04-48829 **CORONER CASE NUMBER:** 04-04421LO
NAME OF DECEASED: BROWN, Henry Lee
INVESTIGATOR: LOREY / COHEN **AGE:** 52 Year(s) **SEX:** Male

SPECIMENS SUBMITTED: ☒ Postmortem Blood ☐ Brain ☐ Stomach Contents ☐ Urine
☐ Antemortem Samples ☐ Liver ☐ Vitreous Humor ☐ Peripheral Blood
Other Specimens:

BLOOD RECEIVED BY: Osuna **FROM:** Hoesch
TISSUE RECEIVED BY: **FROM:**

Findings

Drug	Matrix	Method	Result	Scientist
None Detected				

Analyses

Drug	Matrix	Method	Result	Scientist
Ethanol/Volatiles	Postmortem Blood	Headspace/GC	None Detected	JAH/HXJ
Barbiturates	Postmortem Blood	Immunoassay	Negative	HXJ
Cocaine and/or Metabolite	Postmortem Blood	Immunoassay	Negative	HXJ
Phenethylamines	Postmortem Blood	Immunoassay	Negative	HXJ
Opiates	Postmortem Blood	Immunoassay	Negative	HXJ
Cannabinoids	Postmortem Blood	Immunoassay	Negative	HXJ
Alkaline Drugs	Postmortem Blood	GC/NPD-GC/MS	None Detected	TLB
Benzodiazepines	Postmortem Blood	LC/MS/MS	None Detected	IBC
Strong Acid/Neutral Drugs	Postmortem Blood	HPLC/UV	None detected	RDB

LIMS _____ TR JCD AR 7-12-04
7-12-04

Forensic Scientist: BAISZ July 12, 2004

County of Orange, Health Care Agency, Public Health Laboratory
1729 W. Seventeenth Street, Santa Ana, CA 92706
Douglas F. Moore, Ph.D., Laboratory Director

271

PATIENT #: 04 04421 LO SEX: M AGE: 52 BIRTHDATE:

PATIENT NAME & ADDR: BROWN HENRY LEE

JTC

SHERIFF-CORONER
ATTN: RICHARD L RODRIGUEZ
1071 W SANTA ANA BLVD 714
SANTA ANA, CA 92703

LAB NUMBER: 04.VS.02464
DATE TAKEN: 06/13/04
DATE RECV'D: 06/14/04
SPEC. SOURCE: Blood
SPEC. TYPE:

SUBMITTOR NUMBER 14

---------- (FOLD LINE) ----------

TESTS REQUESTED: HEPATITIS B SURFACE ANTIGEN HEPATITIS C ANTIBODY

RESULTS:

*****FINAL RESULTS*****
Final Date 06/15/04
HEPATITIS C ANTIBODY NOT DETECTED BY EIA
*****FINAL RESULTS*****
Final Date 06/16/04
HEPATITIS B SURFACE ANTIGEN NOT DETECTED BY EIA.

JB

MM
6/18

County of Orange, Health Care Agency, Public Health Laboratory
1729 W. Seventeenth Street, Santa Ana, CA 92706
Douglas F. Moore, Ph.D., Laboratory Director

250

PATIENT #: 04 04421 LO SEX: M AGE: 52 BIRTHDATE:

PATIENT NAME & ADDR: BROWN HENRY LEE

JIC

SHERIFF-CORONER
ATTN: RICHARD L RODRIGUEZ
1071 W SANTA ANA BLVD 714
SANTA ANA, CA 92703

LAB NUMBER: 04.VS.02464
DATE TAKEN: 06/13/04
DATE RECV'D: 06/14/04
SPEC. SOURCE: Blood
SPEC. TYPE:

SUBMITTOR NUMBER 14

---------- (FOLD LINE) ----------

TESTS REQUESTED: HEPATITIS B SURFACE ANTIGEN HEPATITIS C ANTIBODY

RESULTS:

*****FINAL RESULTS*****
Final Date 06/15/04
HEPATITIS C ANTIBODY NOT DETECTED BY EIA

JB

KMJ
6/18